



PATIENT

Bailey Tazumi

SPECIES

Canine

BREED

Miniature Poodle

SEX

Male Neutered

AGE

9 years

WEIGHT

18.3lbs

INTERPRETED BY

Maggie Machen Lamy,
DVM, DACVIM
(Cardiology)

IMAGING PERFORMED BY

Iacovides, DVM

HOSPITAL NAME

Tuxedo Animal
Hospital

REFERRING VET

Dr. Williams

INVOICE

47304

DATE

3/25/26

PRESENTING CLINICAL SIGNS

History: Yearly follow-up echo for monitoring a possible PDA (not confirmed). Grade 4/6 heart murmur. Slight increase in cough.

-Current medications: Pimobendan 5mg/ml 0.45ml BID; Prednisolone 2mg SID, Glucosamine and vitamin supplement for homemade diet.

-Pertinent previous echo findings (2021 Idexx): Suspect small PDA. Echo findings (3/2025 CR): similar results; no definitive diagnosis.

ECHOCARDIOGRAM FINDINGS

2D, m-mode, color flow and doppler imaging is available. Mild thickening of mitral valve leaflets with no prolapse into the left atrial lumen. Trace central mitral regurgitation with mild left atrial dilation. No LV dilation with adequate myocardial function. The tricuspid valve appears normal with no tricuspid regurgitation. Normal right atrial and ventricular diameter and morphology indicating no overt evidence of pulmonary arterial hypertension. The pulmonic and aortic valves are normal in morphology and mobility. Normal pulmonic and mildly elevated aortic outflow velocities with laminar flow. Trace aortic and no pulmonic insufficiency. A jet of diastolic flow is seen in the region of a PDA. No pericardial or pleural effusion noted. No obvious cardiac masses.

CARDIAC CHART

CANINE CARDIAC PARAMETERS	MR VMAX (m/s)	TR VMAX (m/s)	LA/AO (Boon method)	LA/AO (Heart Base; Swe)	FS (%)	EF (%)	EPSS (cm)
NORMAL PARAMETER	4.5-5.5	<2.7	1.3	<1.6	28-40	40-100	<0.6
PATIENT			NM	1.5	50	90	0.3
CANINE CARDIAC PARAMETERS	HR (BPM)	AV VMAX (m/s)	PV MAX (m/s)	BODY WEIGHT (kg)	LA 2D short axis Base view (cm)	LVIDd Avg; 2D and m-mode short axis (cm)	LVIDs Avg; 2D and m-mode short axis (cm)
NORMAL PARAMETER	50-100	0.7-1.7	0.7-1.6	BELOW	BELOW	BELOW	BELOW
PATIENT		1.3	0.9	8.3	2.7	3.0	1.5
*Normal chamber parameters expressed as a mean value (SD)				3	1.27 (5.3)	2.46 (2.46)	1.36 (5.5)
BODY WEIGHT DEPENDENT PARAMETERS				5	1.40 (4.5)	2.74 (5.2)	1.60 (4.7)
*Note: All measurements based upon multi-modal images and methods. An average value is reported.				10	1.50 (3.8)	3.27 (3.5)	2.06 (3.1)
				15	1.83 (2.0)	3.71 (2.4)	2.43 (2.1)
				20	2.02 (1.9)	4.14 (2.2)	2.80 (2.0)
				25	2.18 (2.4)	4.48 (2.9)	3.10 (2.5)
				30	2.33 (3.3)	4.83 (3.9)	3.39 (3.4)
				35	2.48 (4.3)	5.17 (5.0)	3.69 (4.5)
				40	2.62 (5.2)	5.48 (6.1)	3.96 (5.4)
				50	2.88 (7.1)	6.07 (8.3)	4.46 (7.4)

INTERPRETATION OF THE FINDINGS & FURTHER RECOMMENDATIONS

As has been previously discussed, the likely diagnosis is a small hemodynamically insignificant



PATIENT

Bailey Tazumi

SPECIES

Canine

BREED

Miniature Poodle

SEX

Male Neutered

AGE

9 years

WEIGHT

18.3lbs

INTERPRETED BY

Maggie Machen Lamy,
DVM, DACVIM
(Cardiology)

IMAGING PERFORMED BY

Iacovides, DVM

HOSPITAL NAME

Tuxedo Animal
Hospital

REFERRING VET

Dr. Williams

INVOICE

47304

DATE

3/25/26

patent ductus arteriosus (PDA). While the PDA cannot be confirmed on spectral or 2D imaging, color flow through the region is clear. This is a congenital abnormality that has been present since birth. The hemodynamic significance in this particular animal appears low as there is only mild left atrial enlargement despite advanced age. Trace MR and AI are noted, and a baseline BP is recommended. No additional issues are noted in this study.

Given these findings, it is reasonable to continue Pimobendan at this juncture. This patient may develop valve disease with age, and the complexity of issues should continue to be monitored. For now, the hemodynamic significance remains mild.

Assessment of progression in the future will help predict long term prognosis, which is highly variable at this stage (B1). Omega fatty acid supplementation and mild salt restriction may be of some long-term benefit. Monitor for development of a cough, labored breathing, exercise intolerance or collapse episodes.

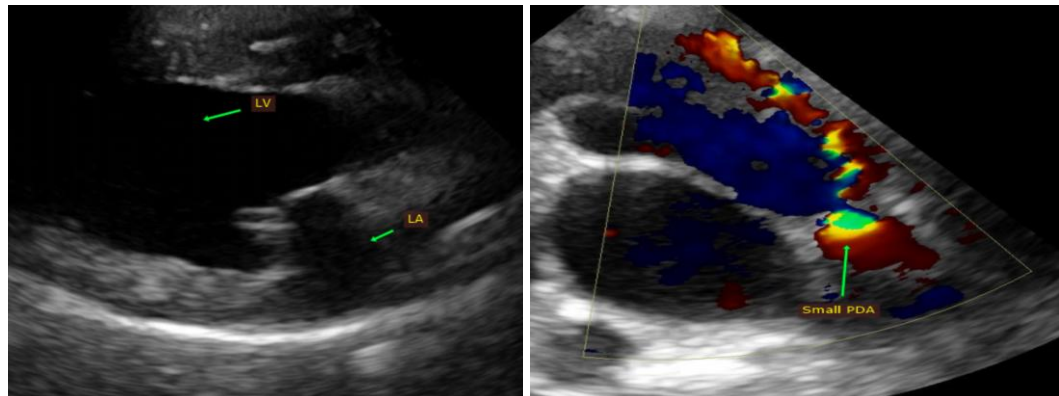
Anesthetic risk is considered mild if needed. Cardiac protective drug choices (opioid/benzodiazepine premedication, propofol or alfaxalone induction, isoflurane gas) are recommended. Pre-oxygenate for 5-10 minutes prior to induction. Monitor for arrhythmias, hypotension, and hypoxia both intra and post-operatively and intervene as necessary. Mild IV fluid restriction is recommended to avoid fluid overload. Avoid heart rate stimulating drugs such as atropine unless clinically indicated.

PLAN

Reasonable to continue Pimobendan 0.3mg/kg PO q12h. Baseline BP recommended.

Recommend conservative monitoring with a recheck echocardiogram annually, sooner if any development of clinical signs.

IMAGES



The information and recommendations provided are based on the images presented by the referring veterinarian. No evaluation can be communicated regarding pathology that was not visible in the image/video clips provided.



PATIENT

Bailey Tazumi

SPECIES

Canine

BREED

Miniature Poodle

SEX

Male Neutered

AGE

9 years

WEIGHT

18.3lbs

INTERPRETED BY

Maggie Machen Lamy,
DVM, DACVIM
(Cardiology)

IMAGING PERFORMED BY

Iacovides, DVM

HOSPITAL NAME

Tuxedo Animal
Hospital

REFERRING VET

Dr. Williams

INVOICE

47304

DATE

3/25/26

Thank you for this referral. This report was generated using transcription software, and minor dictation errors may be present. If the clinical or image interpretation does not parallel your findings or if I can be of any further assistance, please contact me.

Maggie Machen Lamy, DVM

Diplomate of the American College of Veterinary Internal Medicine (Cardiology)

info@sonopath.com